Kor J Med Mycol 5(1), 2000

■ Original Article ■

Efficacy and Safety of a 1-Week Itraconazole 400 mg/day Regimen for Hyperkeratotic Tinea Pedis/Manus: Open Label Multicentre Study

Baik Kee Cho, So Hee Jeong, Dong Won Lee, Chul Jong Park, Sang Chin Lee, Seung Churl Paik, Sang Hyun Cho, Jong Yuk Yi, Tae Yoon Kim, Jin Wou Kim, Si Yong Kim, Ji Yun Cheong* and Kyung Mee Yang*

Department of Dermatology, College of Medicine, The Catholic University of Korea, Seoul, Korea, and Medical Department, Janssen Korea, Seoul, Korea*

INTRODUCTION

Pharmacokinetic studies have revealed the high affinity of itraconazole for keratinous tissue[1~4]. After the agent has reached the keratinous tissue, it does not return into the plasma. The elimination rate of itraconazole from skin is slow and the drug persists in the skin for up to 4 weeks after discontinuation of therapy[2,4~6]. Itraconazole is delivered to the skin through three routes: extensive secretion through the sebaceous glands, moderate secretion through the sweat glands and some incorporation into the basal layer of the epidermis[2,5,7]; in the palmoplantar region, with its thick stratum corneum, there is no sebum excretion and limited sweat excretion.

The present study was designed to assess the efficacy and safety of itraconazole 400 mg/day for 1 week in the treatment of hyperkeratotic type of tinea pedis and tinea manus.

PATIENTS AND METHODS

This open-label, multicentre study involved patients with hyperkeratotic type of tinea pedis or tinea manus. All patients provided written informed consent to participate. Possibly pregnant or lactating women and patients with abnormal liver function, psoriasis or known hypersensitivity to azole antifungal drugs were excluded, as were patients with other dermatophytoses (e.g. onychomycosis, tinea capitis, systemic fungal infection). Concurrent use of drugs that might interact with itraconazole, such as rifampicin, digoxin, phenytoin, oral anticoagulants, cyclosporin A, terfenadine and astemizole, was not permitted. H_2-receptor antagonists and antacids that inhibit absorption of itraconazole were not allowed.

Patients received itraconazole 200 mg twice daily for 1 week and were followed for 4 weeks after active treatment. Clinical and mycological examinations were made at the start of treatment, at the end of treatment and 4 weeks after discontinuation of treatment.

Clinical response was measured by rating four major symptoms of tinea pedis or tinea manus - desquamation, pruritus, erythema/inflammation and fissure - on a four-point scale: 0=absent, 1=mild, 2=moderate and 3=severe. Patients were also assessed on a clinical global evaluation using a five-point scale: cure=

†Corresponding author: Baik Kee Cho, Department of Dermatology, St. Mary's Hospital, The Catholic University of Korea, Yoido-dong 62, Youngdeungpo-ku, Seoul 150-713, Korea

resolution of all clinical symptoms; marked improvement=total clinical score reduced by > 75%; moderate improvement=total score reduced by 50～75%; minimal improvement=total score reduced by 25～50%; and no change=total score reduced by <25%. Response was defined as clinical improvement of more than 50% from baseline (i.e. rating of cure, marked improvement or moderate improvement).

Mycological cure was defined as negative results on both microscopy (KOH) and culture.

The tolerability of the study medication was assessed at the end of the 1-week treatment phase by the patient and the investigator, who provided ratings on a four-point scale: very well tolerated=no adverse events; well tolerated=transient and mild adverse events requiring no management; moderately well tolerated=adverse events requiring medical management but not discontinuation of trial medication.

Adverse effects were recorded at each visit and blood samples were taken at the beginning and end of the 1-week treatment period. If the laboratory finding was abnormal, a third blood sample was taken at week 5.

The analysis was performed using t-test and McNemar's χ test. Data are presented means± SD. Only a per-protocol analysis was undertaken.

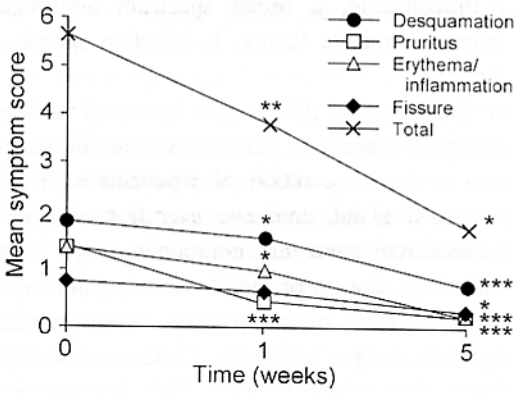

Fig. 1. Mean score of clinical symptoms in 84 Korean patients receiving itraconazole 400 mg/day for 1 week, with a 4-week follow-up. Each symptom was rated on a four-point scale from 0 (absent) to 3 (severe). The total score is the sum of the scores for the four symptoms (thus the total possible score would be 12). * p<0.01, ** p<0.001, *** p<0.0001 versus baseline.

RESULTS

Initially, 97 patients with microscopically or culture-proven hyperkeratotic tinea pedis or manus were entered into the study. However, 13 patients withdrew from the study, the reasons being non-compliance (n=8), adverse effects (n=2) and inappropriate concomitant medication (n=3). Therefore, 84 patients (37 men, 47 women) completed the trial. Of these, 79 had tinea pedis only, two had tinea manus only and three had both tinea pedis and manus. The mean age of patients was 35 years and

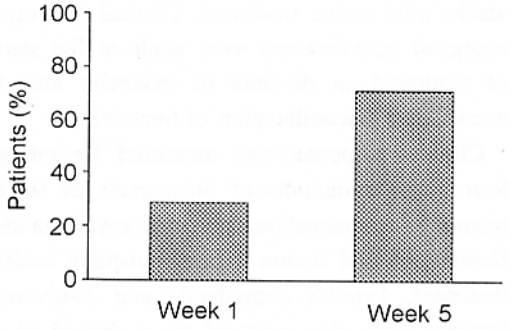

Fig. 2. Clinical response rates in 84 Korean patients receiving itraconazole 400 mg/day for 1 week, with a 4-week follow-up. Response was defined as more than 50% clinical improvement from baseline.

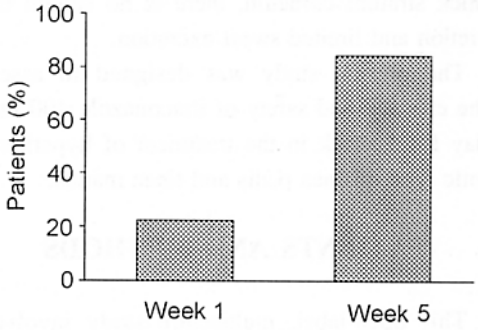

Fig. 3. Mycological cure rates in 84 Korean patients receiving itraconazole 400 mg/day for 1 week, with a 4-week follow-up. Response was defined as negative mycology and culture.

the mean duration of the present infection was 69 months.

At baseline, the proportion of patients affected by the symptoms was as follows: desquamation 98%, pruritus 91%, erythema/inflammation 81% and fissure 48%; after 1 week of treatment, the frequencies were reduced to 77%, 31%, 33% and 35%, respectively. Sex, age, season and duration of disease had no significant effect on symptom severity or clinical response rate.

The scores for each symptom at baseline were as follows: desquamation 1.96±0.78, pruritus 1.48±0.80, erythema/inflammation 1.42±1.01 and fissure 0.80±0.97, giving a total score of 5.65±2.47. At week 1, the mean scores decreased significantly ($p<0.001$) for all symptoms except fissure By week 5, the scores for all four symptoms decreased significantly to the following: desquamation 0.92±0.61 ($p<0.0001$), pruritus 0.35±0.55 ($p<0.0001$), erythema/inflammation 0.39±0.62 and fissure 0.40±0.60, giving a total score of 2.06±1.72 ($p<0.01$) (Fig. 1).

On the clinical global evaluation at week 5, 14% of patients were rated as cured, 27% as markedly improved, 32% as moderately improved, 17% as minimally improved and 10% as unchanged. The clinical response rate increased from 29% at week 1 to 74% week 5 (Fig. 2).

The principal causative pathogens identified were *Trichophyton (T) rubrum, T. mentagrophytes* and *Epidermophyton floccosum*, which occurred in 90%, 9% and 1% of patients, respectively. The mycological cure rate was 23% at week 1 and 85% at week 5 (Fig. 3).

Overall, 98% of patients judged the treatment to be well or very well tolerated. Adverse effects reported during the study included gastrointestinal problems (e.g. abdominal discomfort, diarrhea, nausea, indigestion, constipation) in 14% of patients, skin-related problems (e.g. papular eruption, lip fissure, burning sensation, pruritus) in 4% and other events (e.g. bad breath, fatigue, dizziness) in 3%. Two patients who reported mild nausea and diarrhea discontinued the trial prematurely. Two patients had abnormal laboratory results at week 1: one had increased total bilirubin and the other had increased liver transaminase. In both cases, the pre-treatment values were within the upper limit of normal and the levels returned to normal at week 5. These patients showed no clinical symptoms.

DISCUSSION

Itraconazole, a broad spectrum antifungal agent of triazole family, is effective against a variety of pathogenic fungi such as dermatophytes, mould, and yeasts. There are three delivery routes of itraconazole to the skin. There is extensive secretion of itraconazole via sebaseous gland, moderate excretion via sweat gland, and some incorporation in to the basal layer of the epidermis[2,5,7]. The relative importance of these three routes explains the difference in the drug levels in the stratum corneum of the different body areas. In the palmoplantar region, with a thicker stratum corneum and no sebum secretion and a limited sweat excretion, it takes longer to reach adequate fungicidal concentration in the tissues, where infection resides. So, the standard therapy with itraconazole for hyperkeratotic type of tinea pedis/manus has been 100 mg/day for 30 days.

Recently, pharmacokinetic studies have revealed the high affinity of itraconazole for keratinous tissue. once it has reached in the target tissue, it is rare to return to plasma. Besides, the elimination rate of itraconazole is so slow in this thick stratum corneum that the effect persists for up to 4 weeks after discontinuation of therapy[4]. *In vivo* studies have indicated that the high dose of itraconazole given for a short period is more fungicidal than low dose given longer. Increasing the daily dose to 200 mg results in a more rapid de-

livery of the high drug concentrations to the stratum corneum than a dose of 100 mg[1,2]. That is the initial higher loading dose reaches proportionally higher drug levels in the target tissues. So, it may reduce substantially the length of treatment period[7]. On this pharmacological background, short course at high dose schedule is introduced for treatment of fungal disease requring longer treatment period.

In onycomycosis, pulse therapy (itraconazole 400 mg/day for 7 days in each month, 2 months for finger nail and 3 months for toe nail) is the popular treatment modality nowadays. There are several potential benefits associated with pulse therapy. Firstly, the progressive accumulation of drug and persistent levels in the nail help to prevent the potential development of resistance. Secondly, because plasma levels of drug decline in less than a week, the risk of adverse effects may decrease, which probably reduces the incidence of noncompliance[8].

There are two studies of itraconazole 400 mg 1 week regimen for hyperkeratotic type of tinea pedis/manus treatment. In both studies, they evaluated only 20 patients and reported clinical response rates were 95% and 85%, and mycological cure rates were 85% and 85%, without serious adverse effects[7,9]. In comparison with previous studies, 84 patients were evaluated for efficacy and safety of this regimen. Al. sogair et al[10] evaluated 4294 persons with tinea pedis and indicated that 91.9% of them were interdigital type and only 6.9% were hyperkeratotic type. Because the hyperkeratotic type of tinea pedis/manus associated nail infection is very common, the unassociated form of hyperkeratotic type is not familiar.

In this study, pruritus and erythema/inflammation achieved rapid and significant improvement at early stage. But, fissure did not so, because it takes longer time to recover epithelial damage. But, considering that fissure is the chronic symptom of the hyperkeratotic type, the improvement at week 5 means that the effect of itraconazole is rapid.

In our study, 19.6% patients experienced adverse effects, but these symptoms were not serious that is required to stop this trial or to take action. The gastrointestinal related experience might be reduced, if patients should take the drug with milk, or just after meals.

CONCLUSION

Itraconazole 200 mg twice daily for 1 week regimen appears to be an effective and safe treatment for tinea pedis and tinea manus. The mycological cure rate of 85% achieved in the present study is similar to that reported previously by Decroix et al (n=20, mycological cure rate 85%)[5] and Gupta et al (meta-analysis, n=220, mycological cure rate 76%)[9].

Itraconazole was found to be safe in the present study. The most frequently reported adverse events involved the gastrointestinal system (e.g. abdominal discomfort, diarrhea, nausea, indigestion, constipation), skin (e.g. papular eruption, pruritus) and nervous system (e.g. fatigue). The 1-week regimen has the advantage of reducing the duration of active therapy to 7 days, with the adverse events generally occurring only when active treatment is being administered. Overall, 98% of patients judged the treatment to be well or very well tolerated.

In conclusion, our results indicate that itraconazole 400 mg/day for 1 week in the treatment of tinea pedis or tinea manus is effective and safe. This regimen is expected to encourage the compliance of patients by shortening the active treatment period.

Acknowledgements

This study was supported by Janssen Korea. The statistical analysis was done by Assistant Professor Dong Jae Kim, Department of Statistics, College of Medicine, The Catholic University of Korea. We thank Dr. Aditya Gupta, University of Toronto, Canada, for his help with the manuscript.

REFERENCES

1. Heykants J, Michels M, Meuldermans W, et al. The pharmacokinetics of itracona-zole in animals and man: an overview. In: Fromtling RA, ed. Recent trends in the dis-covery, development and evaluation of antifungal agents. Barcelona, Spain: JR Prous Science Publishers, 1987: 223-249
2. Borgers M, Hayr R, Rinaldi MG, eds. Current Topics in Medical Mycology. Berlin/New York: Springer-Verlag, 1992
3. Pierard GE, Arrese JE, De Doncker P. Antifungal activity of itraconazole and terbinafine in human stratum corneum:a comparative study. J Am Acad Dermatol 1995; 32: 429-435
4. Cauwenbergh G, Degreef H, Heykants J, et al. Pharmacokinetic profile of orally administered itraconazole in human skin. J Am Acad Dermatol 1988; 18: 263-268
5. Decroix J. Tinea pedis (moccasin-type) treated with itraconazole. Int J Dermatol 1995; 34: 122-124
6. Heykants J. Van Peer A, Lavrijsen K, et al. Pharmacokinetics of oral antifungal and their clinical implications. Br J Clin Pract Suppl 1990; 71: 50-56
7. Greer DL, Hay RJ, Itraconazole Monogra-ph: Dermatology. Chester, UK: Adis International Ltd, 1994
8. Odom RB, New therapies for onycomyco-sis. J Am Acad Dermatol 1996; 35: s26-s30
9. Gupta Ak, De Donker P, Heremans, et al. Itraconazole in tinea pedis: a dose of 400 mg/day for 1 week is more effective than 100 mg/day for 30 days or 200 mg/day for 15 days (poster presentation). 54th Annual Meeting of the American Academy of Dermatology, Washington DC, USA, 1996
10. Al. Sogair SM, Moawad MK, Al. Humai-dan YM. Fungal infection as a cause of skin disease in the eastern province of Saudi-Arabia: tinea pedis and tinea manum. Mycoses 1991; 34: 339-344

=국문초록=

각화형 수족부 백선에 대한 Itraconazole 1일 400 mg 1주 요법의 효과 및 안정성: 다기관 연구

가톨릭대학교 의과대학 피부과학교실, (주) 한국얀센 메디칼부*

조백기 · 정소희 · 이동원 · 박철종 · 이상진 · 백승철 · 조상현
이종육 · 김태윤 · 김진우 · 김시용 · 정지윤* · 양경미*

이트라코나졸은 약물역동학적으로 피부 각질에 친화성이 높고 투약 종료 후에도 4주간 지속되며 고용량 단기간 투여가 효과적이라는 것이 알려지면서 각화형의 수장부/족부 백선 치료에도 고용량 단기간 투여법이 시도되고 있다. 본 연구는 각화형의 수장부/족부 백선 환자 97명을 대상으로 이트라코나졸 1일 400 mg을 7일간 투여하여 효과 및 안전성을 평가하였다. 투약 전, 투약 후, 투약 종료 4주후에 임상적, 진균학적으로 효과를 평가하여 임상적으로 73.8%에서 중등도 이상의 개선, 진균학적으로는 84.5%의 완치율을 얻었다. 97.6%의 환자에서 양호한 내약성을 나타내었고, 2.4%에서 위장관 증상, 피부 발진 등이 발생하였으나 특별한 치료 없이 호전되었다. 이상과 같은 결과로 각화형의 수장부/족부 백선 치료에 이트라코나졸 400 mg 7일 투여는 효과적이면서 동시에 안전한 치료법임을 확인하였다. **[의진균지 5(1): 7-12]**

색인 단어: 이트라코나졸, 각화형 수장부/족부 백선, 고용량 단기요법