Phaeohyphomycosis Due to *Exophiala dermatitidis* Successfully Treated with Itraconazole

Dong Seok Kim, Young Mook Yoon and Sang Won Kim

Department of Dermatology, University of Taegu Hyosung School of Medicine, Taegu, Korea

INTRODUCTION

Phaeohyphomycosis is a subcutaneous and systemic infection caused by dark-walled hyphae and differs from chromoblastomycosis in that it has no sclerotic cells. It commonly occurs in a immunosuppressed host. *Exophiala dermatitidis*, common pathogen of phaeohyphomycosis, has been commonly reported in Japan, but very rare in Korea. This report describes a case of phaeohyphomycosis due to *Exophiala dermatitidis* successfully treated with itraconazole.

CASE REPORT

A 66-year-old Korean female farmer had pruritic lesions on her right cheek. She had an 1-year history of slowly growing dark brown pruritic lesions following minor trauma from an apple tree on her right cheek. The lesions were composed of one large irregular bordered brown scaly plaque and multiple satellite papules on erythematous base (Fig. 1). She had a 5-year history of steroid ointment application to relieve itching sensation on her face. Her family history, physical examinations, chest X-ray, ECG and other laboratory tests were unremarkable. However, CD4/CD8 ratio was inversed (0.9) and multi-CMI tests revealed the decreased reaction.

In potassium hydroxide wet mount of skin scraping, uniformly sized brown round structures were arranged in the shape of chains and groups. They were rarely septated. But, there were no hyphae.

Skin biopsy specimens were obtained from the brown plaque. Hematoxylin-eosin-stained sections revealed pseudoepitheliomatous hyperplasia of the epidermis, granulomatous change in the dermis and transepidermal elimination of the round structures (Fig. 2). The giant cells contained brown round cells, which were identical to the round structures seen in skin scraping (Fig. 3). These round cells stained red to PAS stain.

The tissue and skin scrapings were cultured on Sabouraud dextrose agar at 30℃ for 3 weeks each. Both of two cultures showed same colonies, which were dark brown, pasty and marginally velvety with black reverse. The central portion of the colony was yeasty and the growing periphery was mycelial (Fig. 4). Microscopically, numerous oval to round, yeast-like cells produced hyphal structures (Fig. 5). On scanning electron microscopic examination in the peripheral portion of colony, short annellidic conidiogenous cell with detached conidia was found (Fig. 6A, 6B). These fungi grew even at 42℃ and could not assimilate nitrate. The fungus was identified as *Exophiala dermatitidis*.

Treatment was commenced with oral 200 mg

Corresponding Author: Dong Seok Kim, M.D., Department of Dermatology, Catholic Medical Center, 3056-6, Daemyung-dong, Nam-gu, Taegu, 705-718, Korea

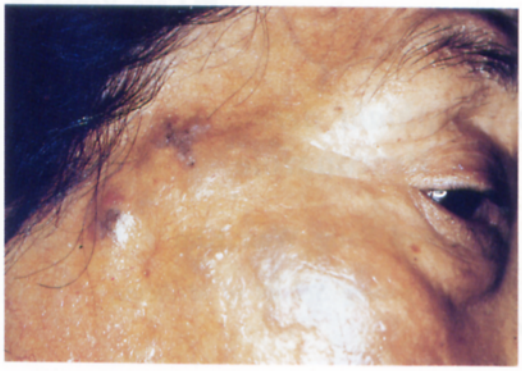

Fig. 1. A large irregular bordered brown scaly plaque and multiple satellite papules on the right cheek.

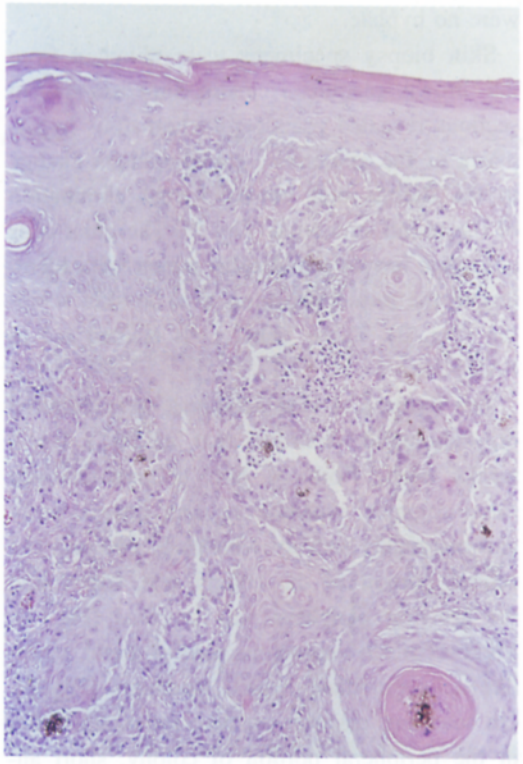

Fig. 2. Hematoxylin-eosin-stained section revealed pseudoepitheliomatous hyperplasia of the epidermis, granulomatous change in the dermis and transepidermal elimination of the round structures (Hematoxylin-eosin stain, ×100).

itraconazole daily. After the initiation of the treatment regimen, the clinical symptoms subsided rapidly. But, pigmentation subsided slow-

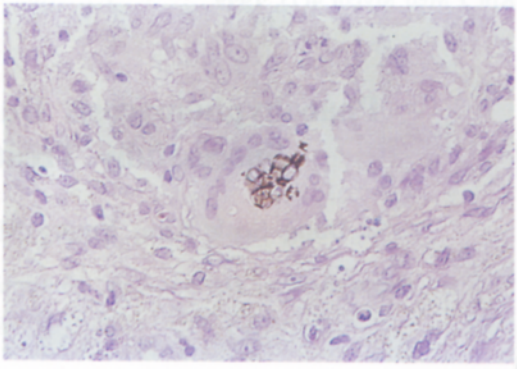

Fig. 3. The giant cell contained brown round cells which were identical to the round structures seen in skin scraping (Hematoxylin-eosin stain, ×400).

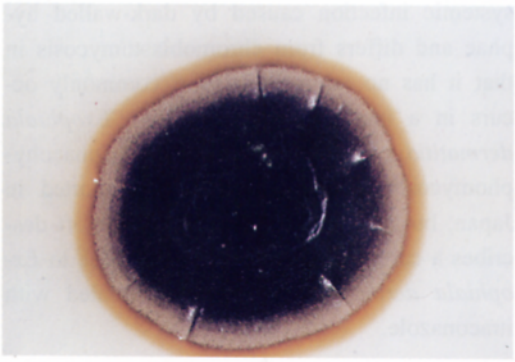

Fig. 4. A tissue from dark brown skin was cultured on Sabouraud dextrose agar at 30℃ for 3 weeks. The central portion of the dark brown colony was yeasty and the growing periphery was mycelial.

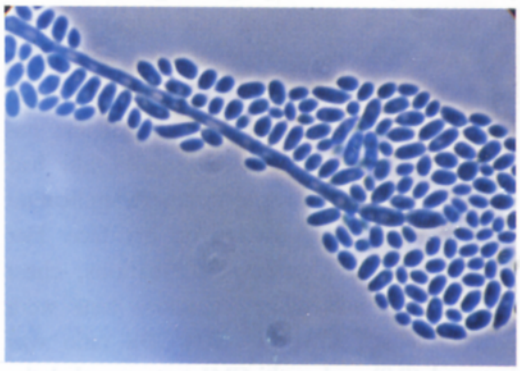

Fig. 5. Numerous oval to round, yeast-like cells and hyphal structures (Sabouraud dextrose agar, lactophenol cotton blue, ×400).

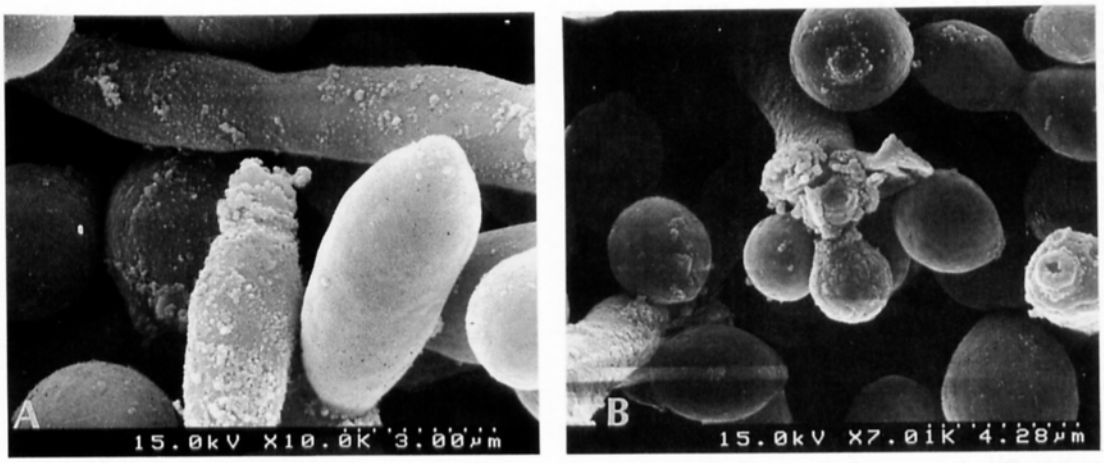

Fig. 6. Short annellidic conidiogenous cell with detached conidia **(A)** and annellation **(B)** on scanning electron microscope (×7,010 (A), ×10,000 (B)).

ly. The potassium hydroxide wet mount of skin scraping was negative after 5 weeks and the tissue culture after 6 weeks. Treatment continued for 16 weeks without significant side effects and there has been no relapse for 1 year.

DISCUSSION

Dematiaceous fungi bear melanin-like pigments on the wall of hyphae and/or spores. They produce a variety of clinical diseases, such as, chromoblastomycosis, phaeohyphomycosis, and eumycotic mycetoma[1]. Phaeohyphomycosis includes infections whose causative agents produce any combination of dematiaceous yeast-like cells, hyphae or pseudohyphae in tissue[2]. The characteristic sclerotic cells seen in chromoblastomycosis are absent in phaeohyphomycosis. The yeast-like cells resemble sclerotic cells, but differ by their thinner cell walls, rare septation in a single plane, and frequent occurrence in chains[3]. The patients of phaeohyphomycosis seem to be immunologically compromised with underlying diseases and locally compromised because of the application of topical corticosteroids[4]. Most of the patients have been associated with rural occupation[3].

The causative agent of this case, *Exophiala dermatitidis*, is an important etiological agent of phaeohyphomycosis[5]. Traumatic incidents lead to the introduction of this fungus into the body[6]. Cutaneous phaeohyphomycosis caused by *Exophiala dermatitidis* produces a lesion that is reddish and slight protruding. The surface of the lesion is uneven and brownish to pink. Flat plaques may be formed with finely or coarsely granular to verrucose surface and fine scaling[3]. Histopathologic examination reveals severe acanthosis and granuloma formation. The dark walled fungal cells are found in the giant cells and tissues. These cells are morphologically characterized by thickened brown wall and sometimes only one transverse septa[3]. In our patient, there were many clustered spherical cells in tissue, but no hyphal structure. In skin and subcutaneous tissues, *Exophiala dermatitidis* tends to develop as spherical cells. In other organs, the mycelial form of the fungus is encountered more often[7].

Exophiala dermatitidis produces slowly growing yeast-like black macroscopic growth. The central portion of the colony is yeasty and the periphery is mycelial[8]. *Exophiala dermatitidis* has short but definite annellide structures on conidiogenous cell on scanning electron microscopic examination[9]. It is the only *Exophiala*

species which is able to grow at 40℃ (even at 42℃) and cannot assimilate nitrate[5].

The treatment of phaeohyphomycosis has been frustrating. Itraconazole, a triazole compound which block ergosterol formation in fungal cell membrane via inhibition of cytochrome P-450 dependent 14α-demethylase, was selected to treat this patient. Itraconazole is a recent systemic antifungal agent useful in the treatment of several deep fungal infections[10]. In phaeohyphomycosis, it is in the same effectiveness range as that reported for amphotericin B and less toxic than other azole and amphotericin B[11]. Itraconazole was effective for our patient and there was no significant side effect during a 4-month course.

Exophiala dermatitidis infection has been commonly reported in Japan[5]. But, only one case of *Exophiala dermatitidis* infection was reported in Korea[12]. Clinical manifestation of the first case was subcutaneous abscess that differed from our case. This case was somewhat interesting because it is very rare in Korea and successfully treated for a short time with oral itraconazole.

REFERENCES

1. McGinnis MR, Hilger AE. Infections caused by black fungi. Arch Dermatol 1987; 123: 1300-1302
2. Ajello L. The gamut of human infections caused by dematiaceous fungi. Jpn J Med Mycol 1981; 22: 1-5
3. McGinnis MR. Chromoblastomycosis and phaeohyphomycosis: New concepts, diagnosis, and mycology. J Am Acad Dermatol 1983; 8: 1-16
4. Matsumoto T, Matsuda T. Chromoblastomycosis and phaeohyphomycosis. Semin Dermatol 1985; 4: 240-251
5. Matsumoto T, Matsuda T, McGinnis MR, Ajello L. Clinical and mycological spectra of *Wangiella dermatitidis* infections. Mycoses 1993; 36: 145-155
6. Matsumoto T, Padhye AA, Ajello L, et al. Critical review of human isolates of *Wangiella dermatitidis*. Mycologia 1984; 76: 232-249
7. Matsumoto T, Ajello L, Matsuda T, Szaniszlo PJ, Walsh TJ. Developments in hyalohyphomycosis and phaeohyphomycosis. J Med Vet Mycol 1994; 32(suppl 1): 329-349
8. Dixon DM, Polak-Wyss A. The medically important dematiaceous fungi and their identification. Mycoses 1991; 34: 1-18
9. Rippon JW. Medical mycology. 3rd ed. Philadelphia: WB Saunders, 1988: 647
10. Rippon JW. A new era in antimycotic agents. Arch Dermatol 1986; 122: 399-402
11. Sharkey PK, Graybill JR, Rinaldi MG, Stevens DA, Tucker RM. Itraconazole treatment of phaeohyphomycosis. J Am Acad Dermatol 1990; 23: 577-586
12. Lee SC, Chun IK, Kim YP. A case of phaeomycotic subcutaneous abscess caused by Wangiella dermatitidis. Kor J Dermatol 1986; 24: 692-696

=국문초록=

Itraconazole로 치료된 *Exophiala dermatitidis*에 의해 발생한 흑색진균증 1예

대구효성가톨릭대학교 의과대학 피부과학교실

김동석 · 윤영묵 · 김상원

흑색진균증 (phaeohyphomycosis)는 흑색을 띄는 균사에 의해 발생하는 피하조직과 전신적인 감염으로 chromoblastomycosis와는 경화성 세포 (sclerotic cell)가 없는 것으로 구분할 수 있다. 이는 주로 면역억제환자에서 발생한다.

66세의 여자농부가 오른쪽 뺨의 소양성 병변을 주소로 내원하였다. 1년전 오른쪽 뺨을 사과나무 가지에 찔린 후 서서히 커지는 진한 갈색의 소양성 병변이 발생하였다. 병변부의 각질과 조직에서는 군집된 원형의 갈색세포들이 관찰되었으며 균사의 구조는 관찰되지 않았다. 피부각질과 조직을 배양한 결과 42℃에서도 자라는 흑색의 집락을 보였고 주사전자현미경상 annellidic conidiogenous cell들을 보여 *Exophiala dermatitidis*로 동정하였다. *E. dermatitidis*는 흑색진균증을 일으키는 주된 원인균으로 일본에서의 보고례는 많으나 한국에는 아주 드물다. 치료는 itraconazole 200 mg을 4개월 동안 매일 경구투여하였다. 일반적으로 흑색진균증의 치료는 어려우나, 본 증례에서는 itraconazole 투여 후 임상적, 진균학적으로 완치를 보였으며 투여기간 중 특별한 부작용은 관찰되지 않았다.

[Kor J Med Mycol 4(1): 79-83]

색인단어: 흑색진균증 (Phaeohyphomycosis), *Exophiala dermatitidis*, Itraconazole